



PATIENT

Sadie Athey

PRESENTING CLINICAL SIGNS

History: Has a grade 3/6 murmur that was not noted in previous appointment. Asymptomatic. Pet came in for spay. Feline Triple SNAP Test: Negative.

SPECIES

Feline

ECHOCARDIOGRAM FINDINGS

2D, m-mode, color flow and doppler imaging is available. The left ventricular wall is normal in dimension. The endocardium appears fibrotic and irregular. False tendon. Mild remodeling. The papillary muscles appear normal. The left atrium is normal in size. The right atrium is normal in size. The right ventricle appears normal. The mitral valve is normal in structure and mobility. No MR. The tricuspid valve appears normal in structure and mobility. No TR. Blood flow through both the LVOT and RVOT is normal. Trivial aortic and pulmonic insufficiency. No effusions seen. No tumors noted.

BREED

DLH

SEX

Female

CARDIAC CHART

AGE

17 weeks

WEIGHT

5.12lbs

INTERPRETED BY

Maggie Machen Lamy,
DVM, DACVIM
(Cardiology)

IMAGING PERFORMED BY

Potomac Mobile
Veterinary Ultrasound

HOSPITAL NAME

Banfield Pet Hospital
- Leesburg Classic

REFERRING VET

Dr. Jarrett

INVOICE

22834

DATE

2/28/22

FELINE CARDIAC PARAMETERS	BODY WEIGHT (kg)	HR (BPM)	IVSd (cm) <small>(Moise, Pipers)</small>	LVIDd (cm) <small>(Moise, Pipers)</small>	LWVd (cm) <small>(Moise, Pipers)</small>	FS (%)	EF (%)
NORMAL PARAMETER	-----	150-240	0.35-0.55	<2 (mean 1.5)	3.5-0.55	35-67	80-100
PATIENT	2.3	144	0.4	1.35	0.4	43	78
FELINE CARDIAC PARAMETERS	LA/AO (Boon)	LA/AO HEART BASE (Swe) <small>(Abbott)</small>	LA 2D short axis Base view (cm) <small>(Abbott)</small>		LVOT VEL (m/s)	RVOT VEL (m/s)	E max (m/s)
NORMAL	<1.5	<1.3	<1.2		<1.6	<1.3	<0.9
PATIENT	NM	1.1	1.0		1.1	1.1	NM

**Note: All measurements based upon multi-modal images and methods. An average value is reported.
Adapted from June Boon, Veterinary Echocardiography, 1998
Abbott J & MacLean H JVIM 2006;20: 111-119, Moise et al. Am J Vet Res 47:1476, 1986. Pipers et al. Am J Vet Res 40:882, 1979.*

INTERPRETATION OF THE FINDINGS & FURTHER RECOMMENDATIONS

Overtly normal cardiac structure and function. No significant valve leaks are noted, and flow through the great vessels is documented normal in velocity. That being said, the lining of the LV is subjectively more fibrosed than is suspected in a 4-month-old kitten and periodic monitoring is advised. A small aortic leak is identified which would not be heard on exam. No obvious congenital defects are seen; however, it is important to note that small defects are easily missed especially in young cats, and if suspicion persists consider referral to local Cardiologist for advanced imaging.

Given these findings and a normal LA dimension, no medications are indicated.

No cardiac contraindication for general anesthesia.

Monitor at home for signs of cardiac compromise, including respiratory changes and/or signs of a blood clot event (paralysis, neurologic changes).



PATIENT

Sadie Athey

Assuming the murmur persists or worsens, referral to a local Cardiologist can be considered. If declined, reassess in 6-12 months.

SPECIES

Feline

BREED

DLH

SEX

Female

AGE

17 weeks

WEIGHT

5.12lbs

INTERPRETED BY

Maggie Machen Lamy,
DVM, DACVIM
(Cardiology)

IMAGING PERFORMED BY

Potomac Mobile
Veterinary Ultrasound

HOSPITAL NAME

Banfield Pet Hospital
- Leesburg Classic

REFERRING VET

Dr. Jarrett

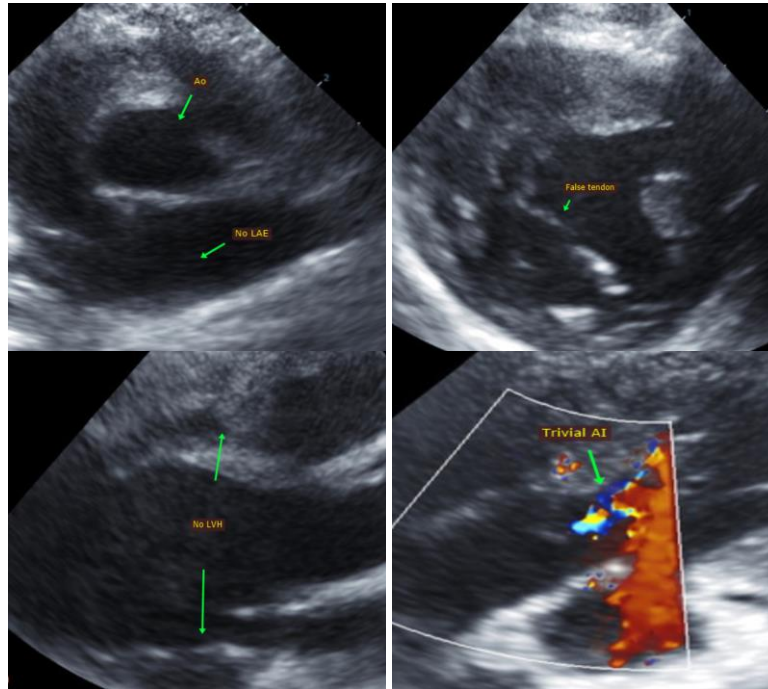
INVOICE

22834

DATE

2/28/22

IMAGES



The information and recommendations provided are based on the images presented by the referring veterinarian. No evaluation can be communicated regarding pathology that was not visible in the image/video clips provided.

Thank you for this referral. This report was generated using transcription software, and minor dictation errors may be present. If the clinical or image interpretation does not parallel your findings or if I can be of any further assistance, please contact me.

Maggie Machen Lamy, DVM
Diplomate of the American College of Veterinary Internal Medicine (Cardiology)
info@sonopath.com



PATIENT

Sadie Athey

SPECIES

Feline

BREED

DLH

SEX

Female

AGE

17 weeks

WEIGHT

5.12lbs

INTERPRETED BY

Maggie Machen Lamy,
DVM, DACVIM
(Cardiology)

**IMAGING
PERFORMED BY**

Potomac Mobile
Veterinary Ultrasound

HOSPITAL NAME

Banfield Pet Hospital
– Leesburg Classic

REFERRING VET

Dr. Jarrett

INVOICE

22834

DATE

2/28/22